THE VALUE OF CT AND CTA IN ACUTE STROKE

Timothy G. Lukovits, M.D.

Department of Neurology, DHMC

Medical Director, NH Stroke Collaborative

DISCLOSURES/COI

- None
- I don't use AI software for acute stroke management at this time

THE VALUE OF PLAIN CT + CTA

- Identify LVOs, and if CTA done "up-front", reduce DIDO times
- CTA acquisition <5 min (don't need fully processed images for acute decision-making)
- Can help identify stroke mimics if negative (not perfect, can have a stroke without a CT/CTA abnormality)
- Identify vascular basis of acute vertigo
- May help reduce unnecessary transfers
- Better than MRA for showing aneurysms and CVT and characterizing complex carotid plaques

Acute Stroke Imaging and Triage Algorithm

Adapted with permission from the work of the Mass. CTA Workgroup

American Heart Association®

Suspected Stroke? Candidate for thrombolysis or thrombectomy?
Last Seen Well <24hours?
NIHSS ≥6 or FAST-ED Score ≥ 4*

ALL yes

STAT CT Head, CTA head and neck

Hemorrhage on CT?

yes → Follow hemorrhage evaluation and management pathway

no

Candidate for IV thrombolytic

no

yes

Administer thrombolytic

Large vessel occlusion on CTA

yes → Review Embolectomy Criteria and consider emergent transfer to thrombectomy center

no → Follow stroke management pathway

TIME IS BRAIN

EVERY SECOND COUNTS!

DO: get CT and CTA together, without taking patient back to ED between the scans

DO *NOT*: wait for renal function labs if patient has no known history of renal dysfunction

* some hospitals may wave this requirement for efficiency

Dartmouth-Hitchcock

Guide for the Identification and Triage of Possible Mechanical Embolectomy Candidates with Acute Ischemic Stroke

CONTENTS

A. Acute Stroke Imaging and Triage Algorithm
B. FAST-ED Stroke Severity Scale
C. Mechanical Embolectomy Initial Screening Criteria
D. Expanded Regional CTA Use for Stroke
E. CT/CTA Technical and practical notes
F. CTA Technical Parameters (for Siemens and GE Scanners)

Disclaimer
The medical information contained in this guide is designed to be used only as a medical and educational reference tool. It is not intended to be used as a diagnostic decision-making system and must not be used to replace or overrule a medical provider's judgment or diagnosis. The responsibility for decisions regarding actual patient care rests solely with the provider treating a patient.

May, 2019

MAY 26, 2020
41 YO M FROM FAR NORTHERN NEW ENGLAND

Patient expected to arrive at destination this day

1628 Request Began — Jennifer L Dole

Ownership claimed by Jennifer L Dole

1629 [redacted]

Contact Role: Referring Provider
Entered By: Jennifer L Dole

Unresponsive at work, pt has been at hospital for 5 hrs
AMS, 143 red cells CSF
Ativan given
+THC, buprenorphine
Ct head -

Vitals

Temp	HR	RR	B/P	O2 Sat	FiO2
afebrile	54	14	123/71	97%	RA

Entered Kacie R Boyle, RN
By:
Updated Kacie R Boyle, RN
By:

Ativan 2mg given due to twitching. Pt unable to follow commands, carry on conversation.

"clean" for two years.

Bell's Palsy deficit- Right sided upon arrival. Since resolved.

CT CT HEAD/BRAIN WO CONTRAST

CT SCAN OF THE HEAD WITHOUT CONTRAST:

INDICATION: Altered mental status

COMPARISON: None

Multiple scans obtained from base of skull to vertex. N
extra-axial blood. Ventricles are normal in size and co
No midline shift or mass effect. No areas of focal pare
density or sulcal effacement noted to suggest acute cort
No other intracranial abnormality is evident.

IMPRESSION: No acute abnormality noted.

CT 11:53AM (4.5 HRS PRIOR TO FIRST CALL TO TX CENTER)

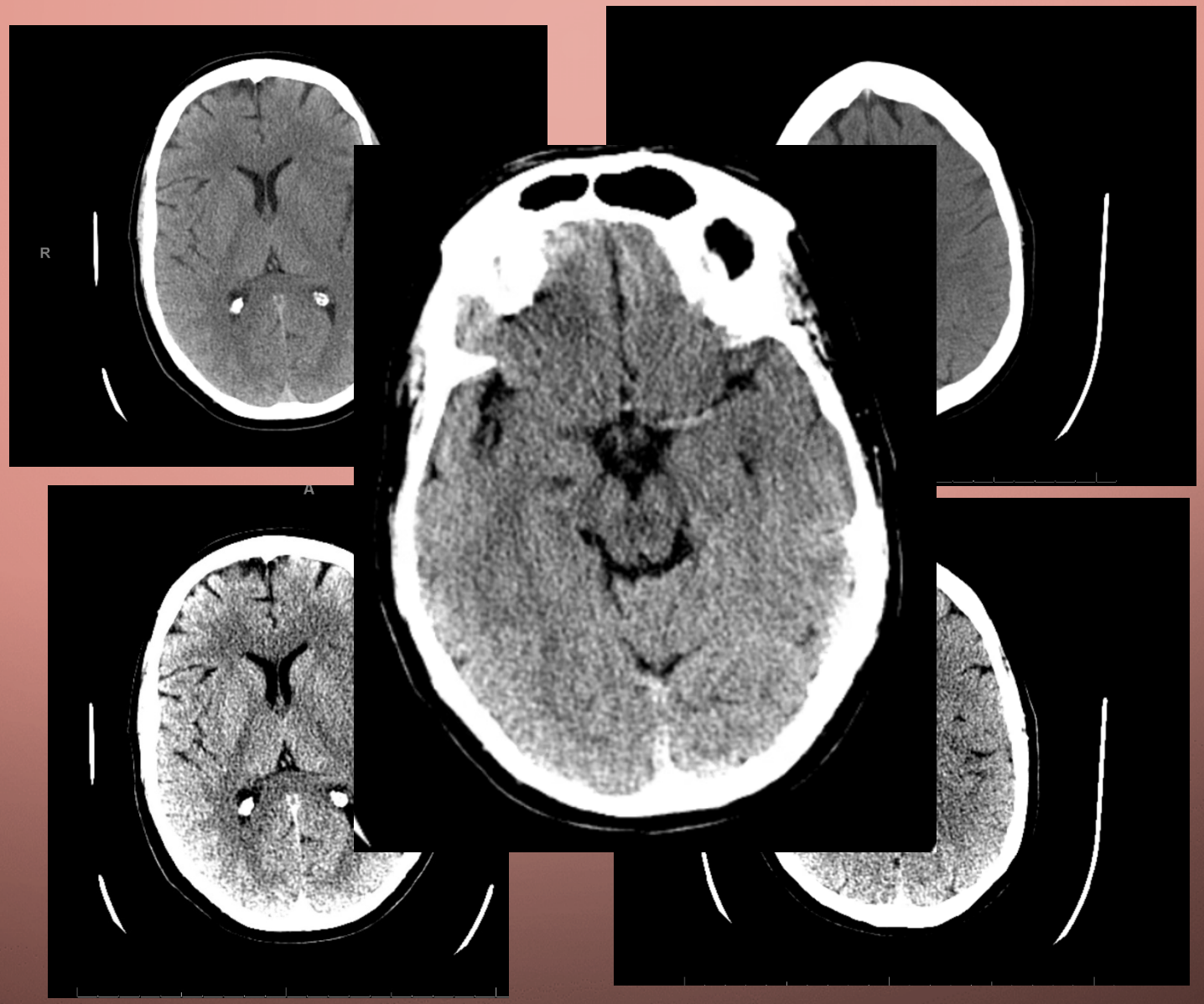

"stroke windowing" with more contrast

CTA 23:40

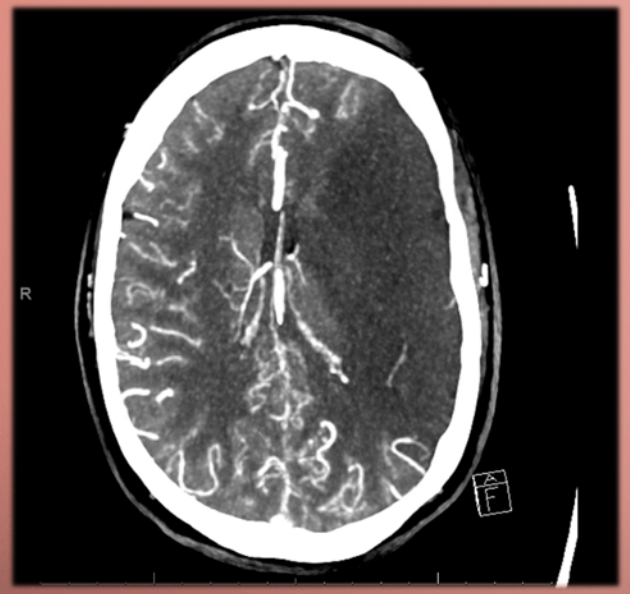

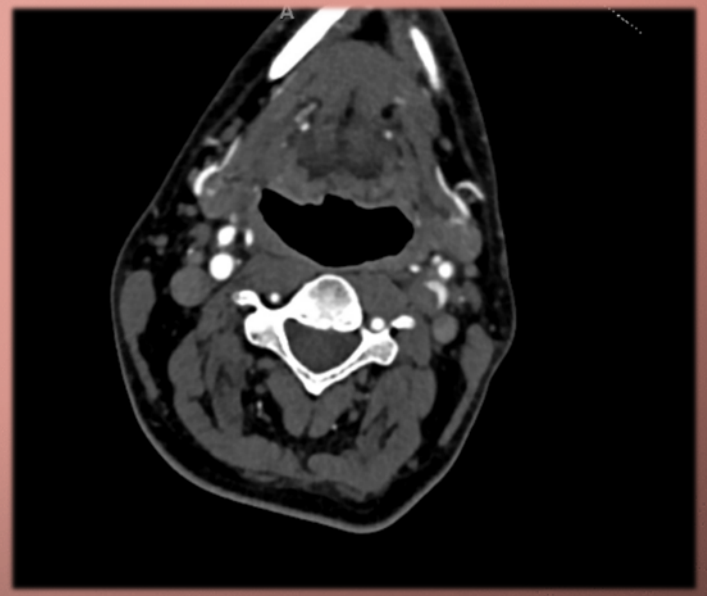

LARGE DWI LESION AND FOLLOWING HEMI-CRANIECTOMY

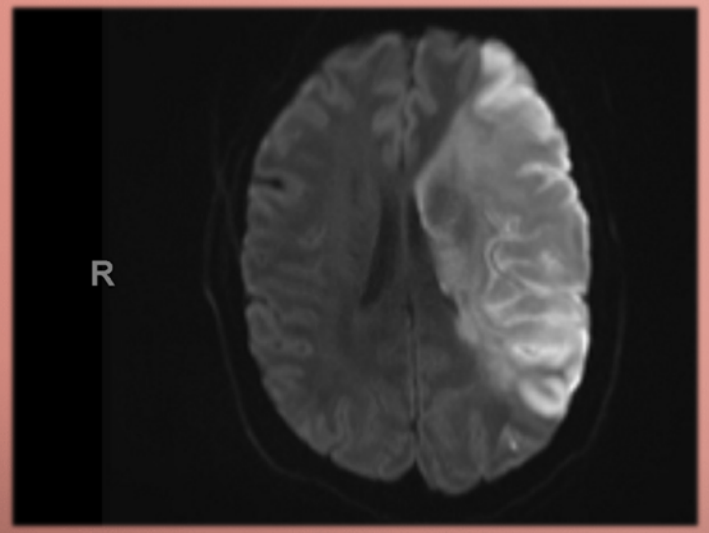

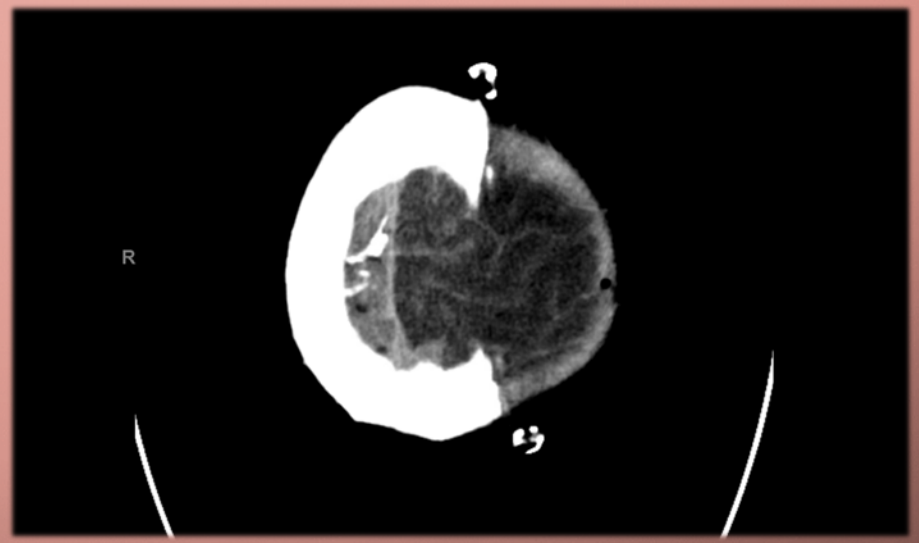

"SUDDEN DIZZINESS WITH NORMAL HEAD CT"

- 47 yo M, hx HTN
- April 23rd was in bathroom and suddenly felt dizzy like on a ship. Took a shower but yelled out to his wife. Got out of shower, felt sweaty and veered to the L and almost went to the ground, vomited a few times. In the ED, his vertigo seemed to mostly resolve and BP initially 248/149. CT head read as normal and he was admitted for "hypertensive emergency".

- In retrospection and with correct “windowing” of the same CT scan…

- The next day there was discussion about DC to home but he reported ongoing head and neck pain and that he felt dizzy whenever he got up. In fact, whenever the bed automatically adjusted to his movements, he had vertigo and at 300 pounds, this happened a lot. ICU attending noted nystagmus and so MRI done.

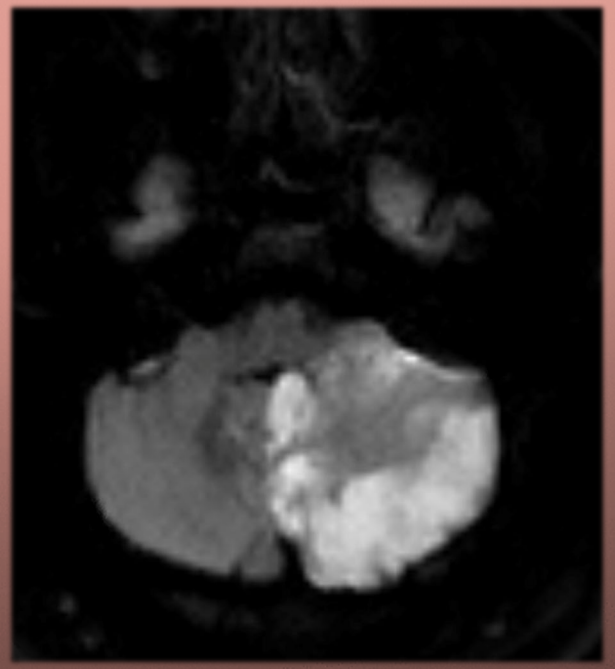

SUDDEN DIZZINESS WITH "NORMAL CT" CASE 2
BEDSIDE VESTIBULAR TESTING NOT POSSIBLE

nml, no rash
, dry
t

EMITIES
-tender
ROM
pedal edema

RO / PSYCH
ented x4
N's nml (2-10)
otor nml
ensation nml
ood / affect nml

itations – 34

__cyanosis / diaphoresis / pallor
__rash / embolic lesions
__signs of IVDA
__pressure ulcer location

__pedal edema
__calf tenderness
__Homan's sign / cords

__disorientated to
person place time situation
__speech / cognition abnormalities
__weakness / sensory loss facial droop
__depressed mood / affect
not able to perform
Dicks Hospital 2° to weakness

ventricular atrial
Tachycardia sinus ventricular
paroxs. supraventricular
Pulmonary Embolus
Valvular Heart Disease
WPW Syndrome
weakness / A-fib / hypokalemic

DISPOSITION DECISION TIME- 8:51 ☐ transferred ☐ home
☐ expired ☐ AMA
DISPO TIME 9:35 ☑ admit __POA pressure ulcer / UTI (foley)
CONDITION- ☑ good ☐ fair ☐ poor ☐ critical ☐ improved

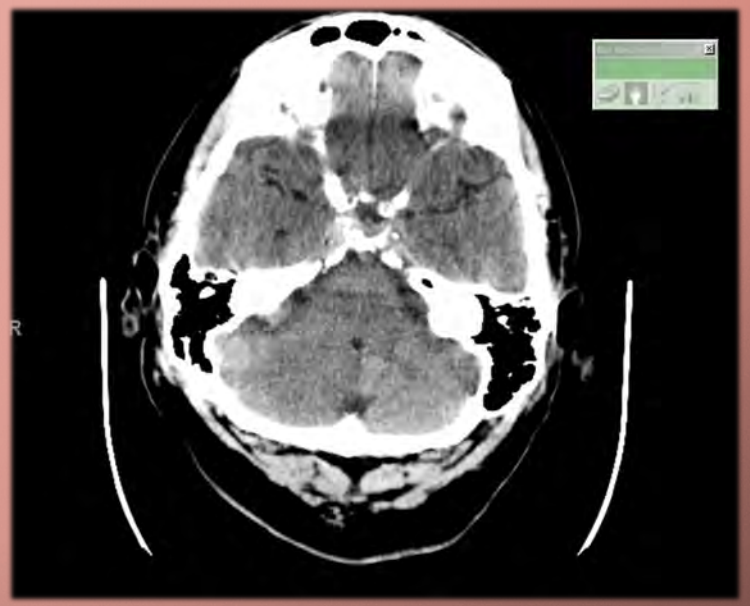

IMPRESSION:
No acute intracranial process. No evidence of acute hemorrhagic stroke. Findings for ischemic stroke could be missed early on. If there is persistent clinical concern MRI with diffusion weighted sequences are recommended.

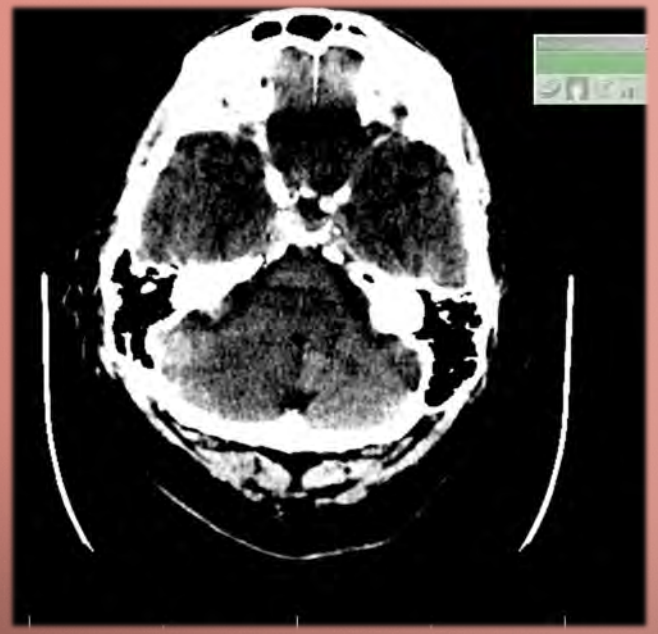

DX ABDO
DX ABDO
DX CHES
CT HEAD
CT HEAD
DX CHES
DX ABDO
CT HEAD
MR HEAD
RF GI
CT HEAD
CR CHES
10/04
10/04
10/04
10/04
10/04
10/04
10/04
10/03
10/03
10/03
10/02
10/02
10/3/2013 17:59:28
Acc# 5530241
10/3/2013 17:43:17
Acc# 5530241
5
A
R
19
S
A
MRI^BRAIN
AXIAL T2
Series #9
27 Images
TE:122.0/TR:5370/SE
5.0mm/6.0mm
MRI^BRAIN
T2 SAG FLAIR
Series #3
40 Images
TE:90.0/TR:8560/IR/SE
3.0mm/3.0mm

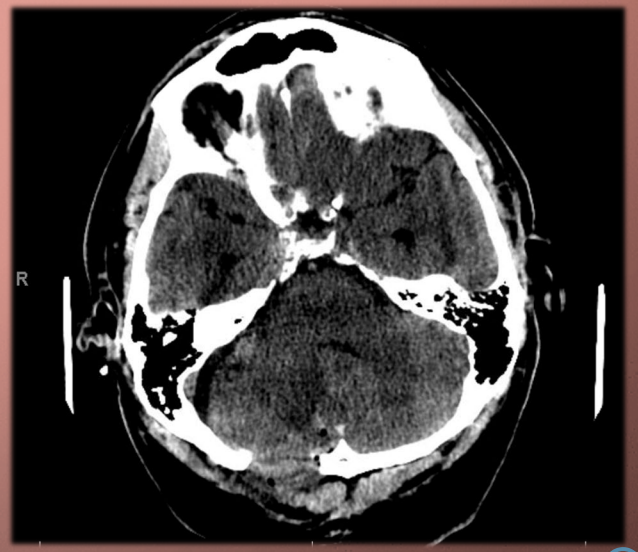
R

DIZZINESS WITH REALLY NORMAL HEAD CT

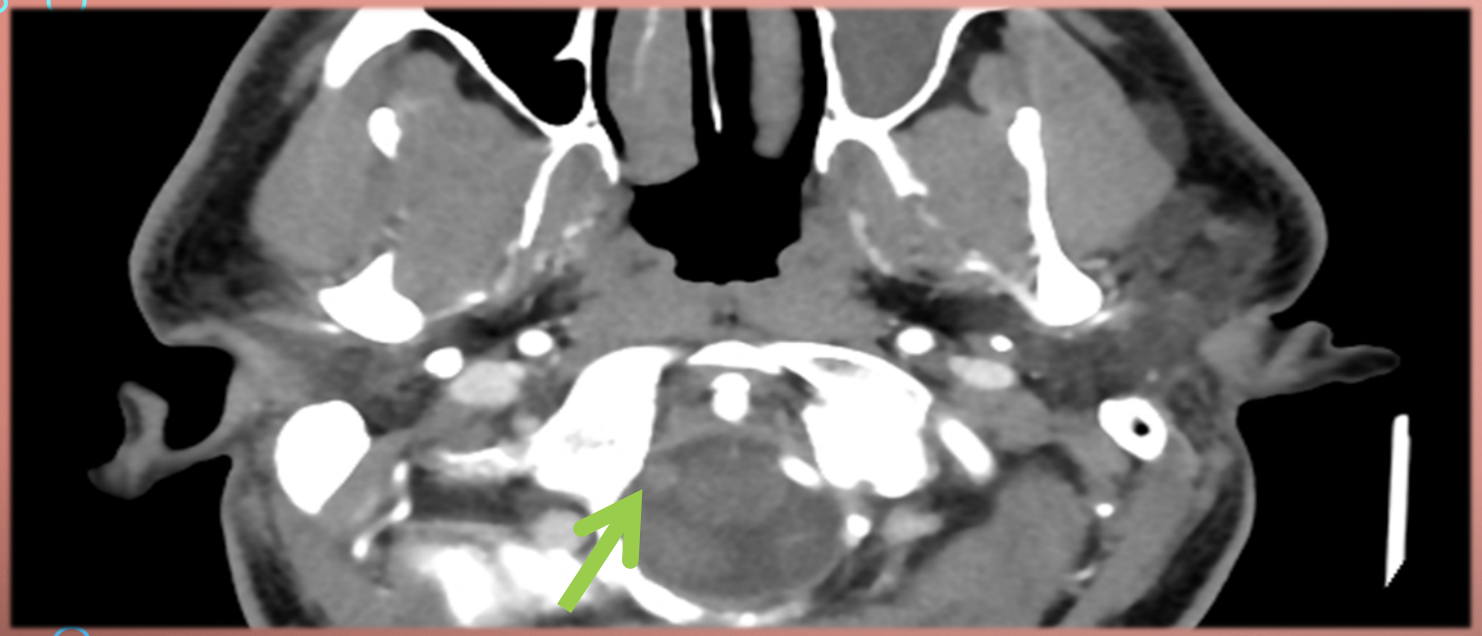

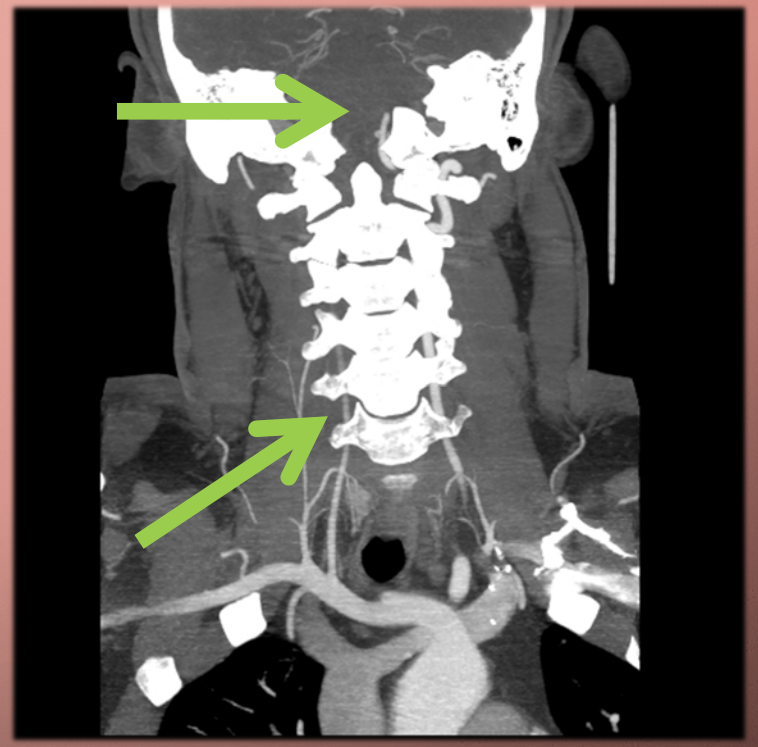

CTA: R vertebral artery occlusion

“HINTS” BATTERY ON NORMAL SUBJECT: IT’S NOT THAT EASY!

PRESENCE OF OCCLUSION

igure 1. Computed tomography angiography (CTA) showing a atient with a clearly delineated left middle cerebral artery M1 seg- nent occlusion.

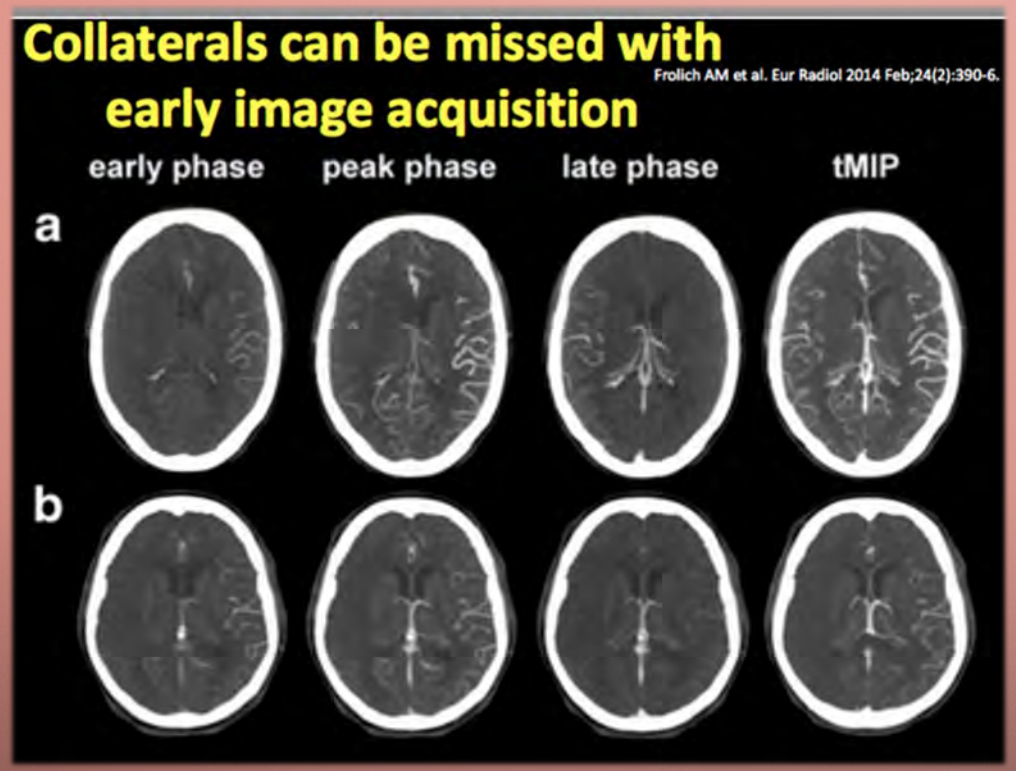
Collaterals can be missed with
early image acquisition
Frolich AM et al. Eur Radiol 2014 Feb;24(2):390-6.
early phase
peak phase
late phase
tMIP
a
b

Good

Bad

GRADE OF COLLATERALS PREDICT OUTCOME AFTER THROMBECTOMY

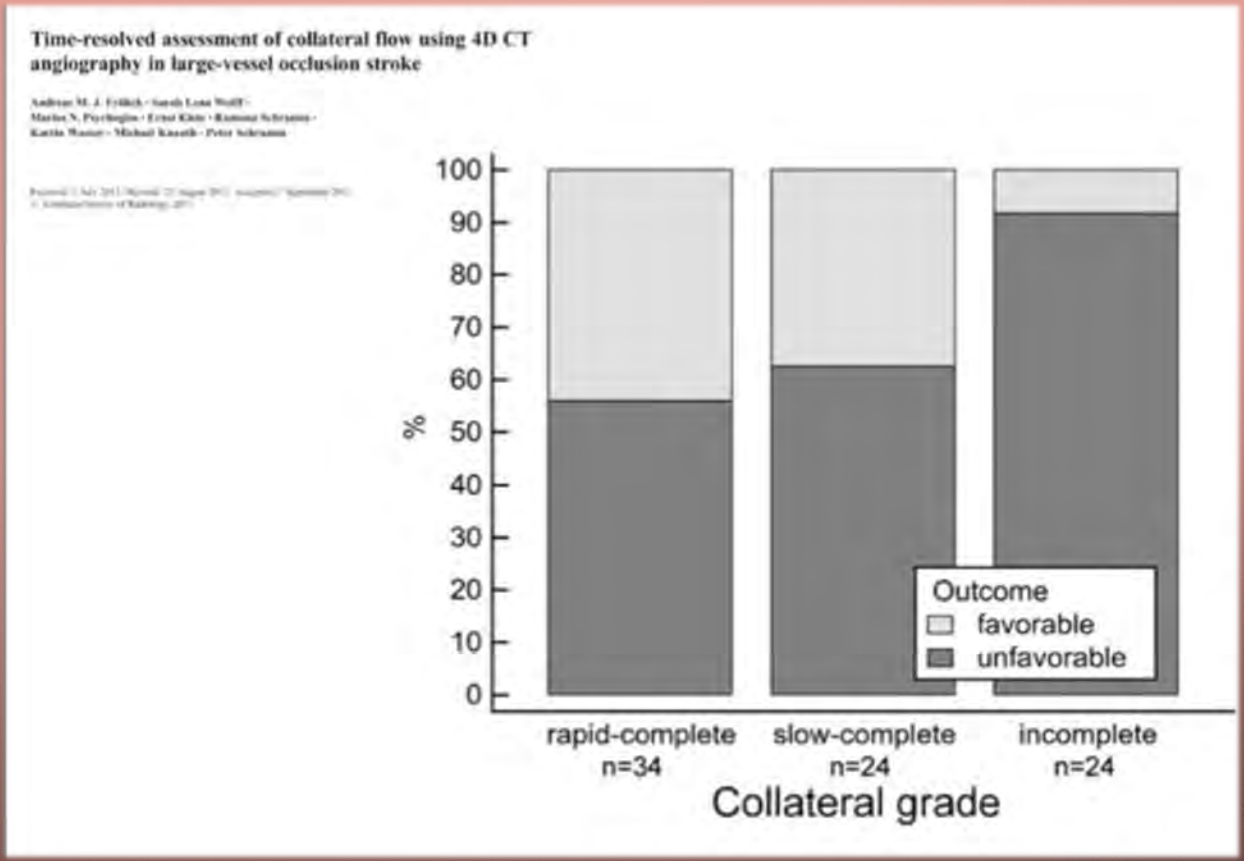

CAROTID ARTERY DISSECTION

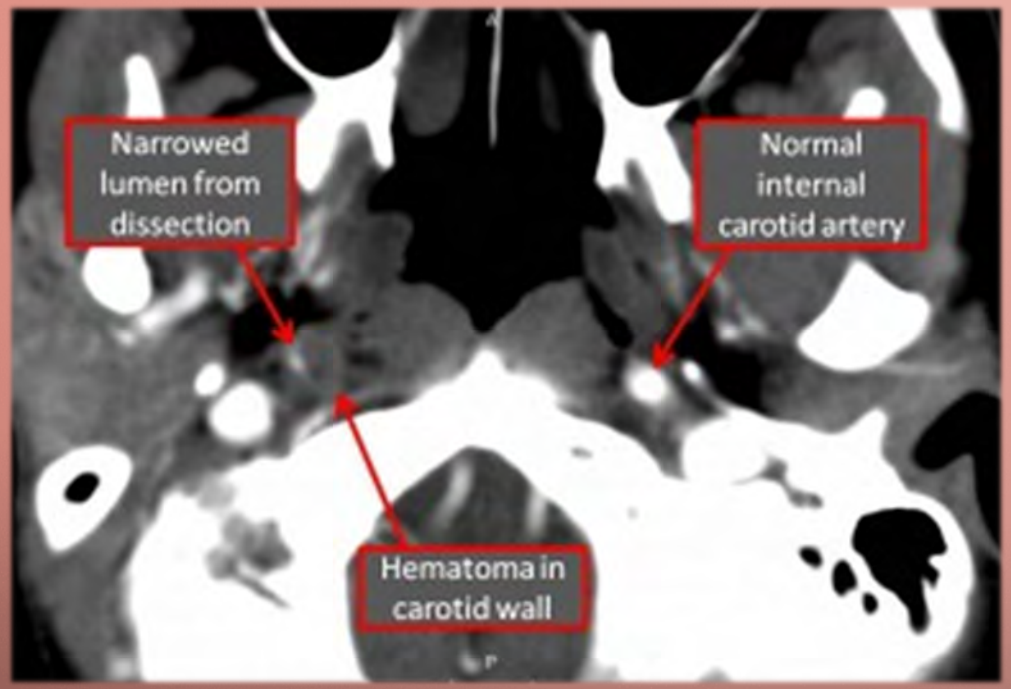

DISTAL VASOCONSTRICTION

“SPOT SIGN” AND HEMATOMA EXPANSION

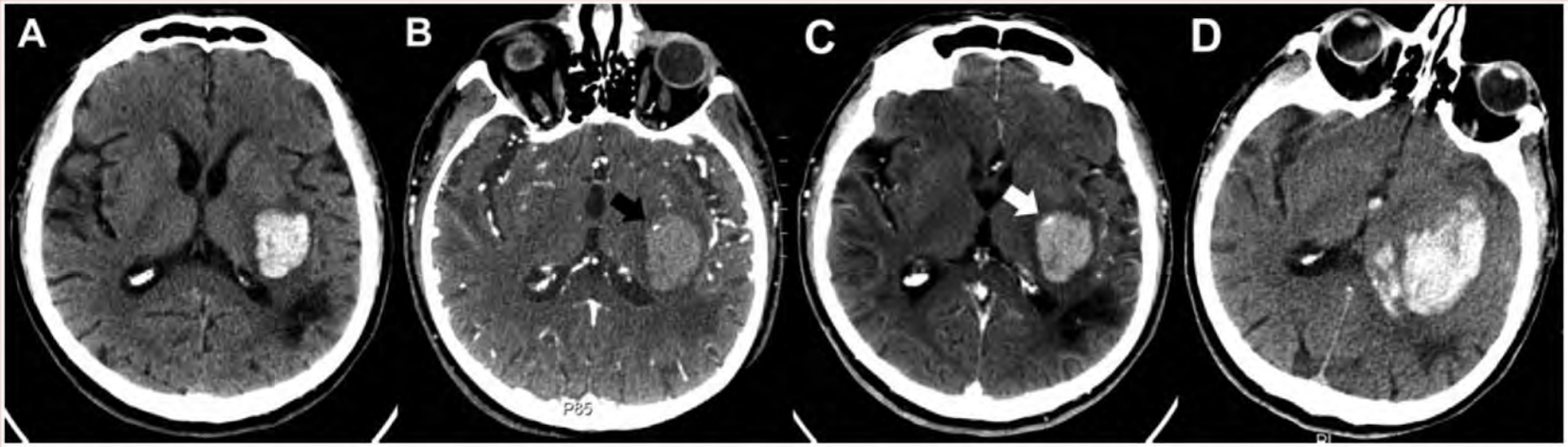

Figure 1. Patient with spot sign, demonstrating extravasation and hematoma expansion. CT slice selection has been optimized for hematoma configuration, not for head position. A, Unenhanced CT demonstrates left posterior putaminal and internal capsule hematoma with mild surrounding edema. An old parieto-occipital infarct is seen posterior to this. B, A small focus of enhancement is seen peripherally on CTA source images, consistent with the spot sign (black arrow). C, Postcontrast CT demonstrates enlargement of the spot sign, consistent with extravasation (white arrow). D, Unenhanced CT image 1 day after presentation reveals hematoma enlargement and intraventricular hemorrhage.

CEREBRAL VEIN THROMBOSIS (CTV VS MRI/MRV)

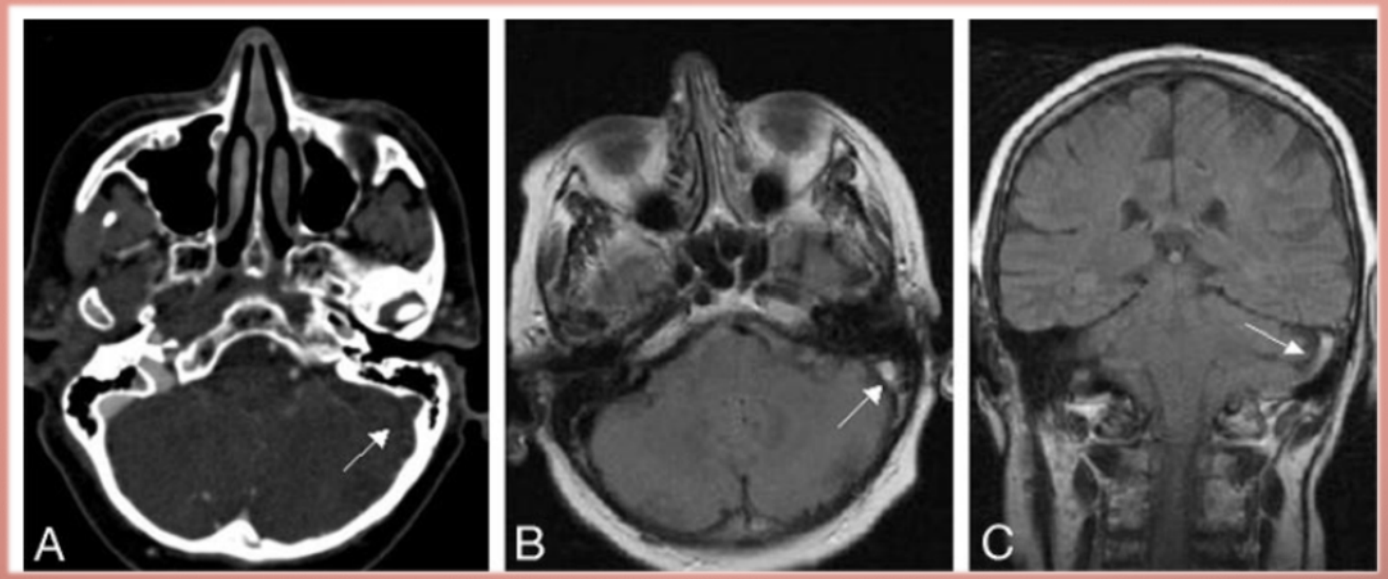

NEW HEADACHE AND ? CEREBRAL VEIN THROMBOSIS WITH DECREASED FLOW IN TRANSVERSE SINUS

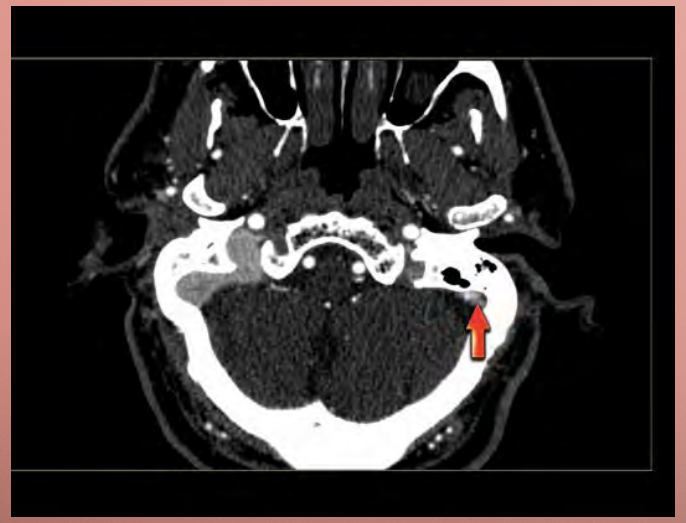

Normal “hypoplastic” left transverse sinus/sigmoid sinus

CT/CTA Imaging
Technical and practical notes:

Before the Arrival of the Patient

- The entire stroke team must keep in mind that "time is brain" and that everything should be prepared for when the patient arrives.
- The activation of the stroke code leads to stopping any non-emergency work at the designated CT scanner.
- The power injector must be loaded with 80 mL of nonionic contrast material (300 mg of iodine per ml).
- In addition, the emergency/radiology department nurse has to gain adequate peripheral venous access with an 18–20-gauge needle to support the 4-5 mL/sec injection rate.
- Any metallic hardware, including dental and hair prostheses, should be removed from the patient.
- The right arm is preferentially selected for IV placement to avoid streak artifacts in the mediastinum from contrast material retained in the left subclavian vein with a left-arm injection.
- The antecubital fossa is preferred for intravenous access over arm-vein or hand-vein access.
- If present. a history of a severe contrast allergy, may contra-indicate doing a CTA.

CT Protocol

- The goal of CT/CTA imaging for acute stroke patients is to obtain the following, in order of importance:
  - CT head. Non-contrast
  - CTA head and neck *(preferably with multiphase imaging of the head).*
  - Axial, sagittal, and coronal *overlapping MIP reconstructions*

- Nonenhanced CT and CT angiography can be performed as a single examination with two separate acquisitions.
- The examination is frequently completed and analyzed within 15 minutes in a real clinical setting using new-generation multidetector CT scanners. A recommended protocol is enclosed.

Nonenhanced CT

- Nonenhanced scanning must be performed as soon as possible after the stroke code has been activated.
- CT is important for the detection of hemorrhage or other possible mimics of stroke (eg, neoplasm, arteriovenous malformation) that could be the cause of the neurologic deficit. Recent hemorrhage is a contraindication to revascularization therapies.
- The second role of nonenhanced CT is the detection of ischemic signs of established infarction. The main CT finding is a hypoattenuating area within a vascular territory.

Dartmouth-Hitchcock

Guide for the Identification and Triage of Possible Mechanical Embolectomy Candidates with Acute Ischemic Stroke

CONTENTS

A. Acute Stroke Imaging and Triage Algorithm
B. FAST-ED Stroke Severity Scale
C. Mechanical Embolectomy Initial Screening Criteria
D. Expanded Regional CTA Use for Stroke
E. CT/CTA Technical and practical notes
F. CTA Technical Parameters (for Siemens and GE Scanners)

Disclaimer
The medical information contained in this guide is designed to be used only as a medical and educational reference tool. It is not intended to be used as a diagnostic decision-making system and must not be used to replace or overrule a medical provider's judgment or diagnosis. The responsibility for decisions regarding actual patient care rests solely with the provider treating a patient.

May, 2019

WHY IS THE R ARM PREFERRED?

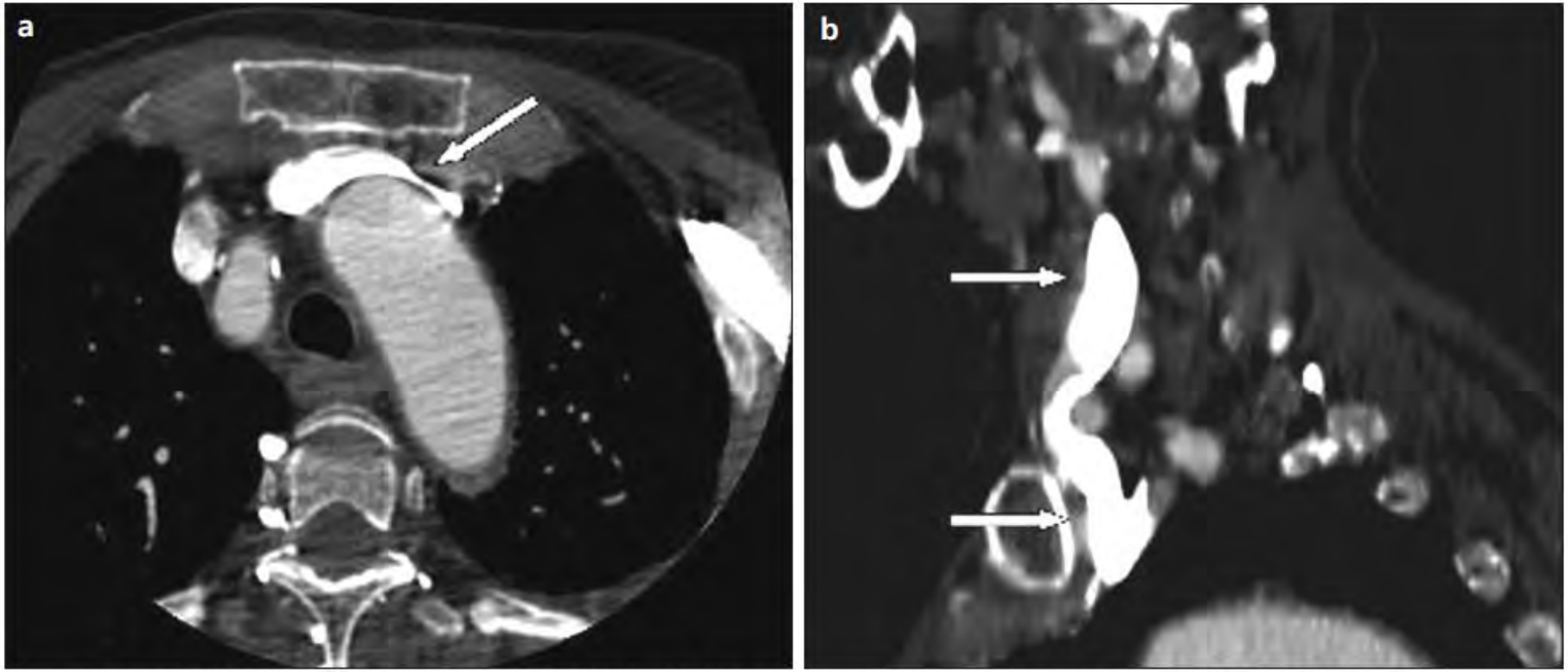

Figure 1. a, b. Axial CT image **(a)** demonstrating brachiocephalic vein compression *(arrow)*. Sagittal reformatted image **(b)** showing reflux of contrast medium into the left IJV *(arrows)* due to constitutional retrosternal narrowing.

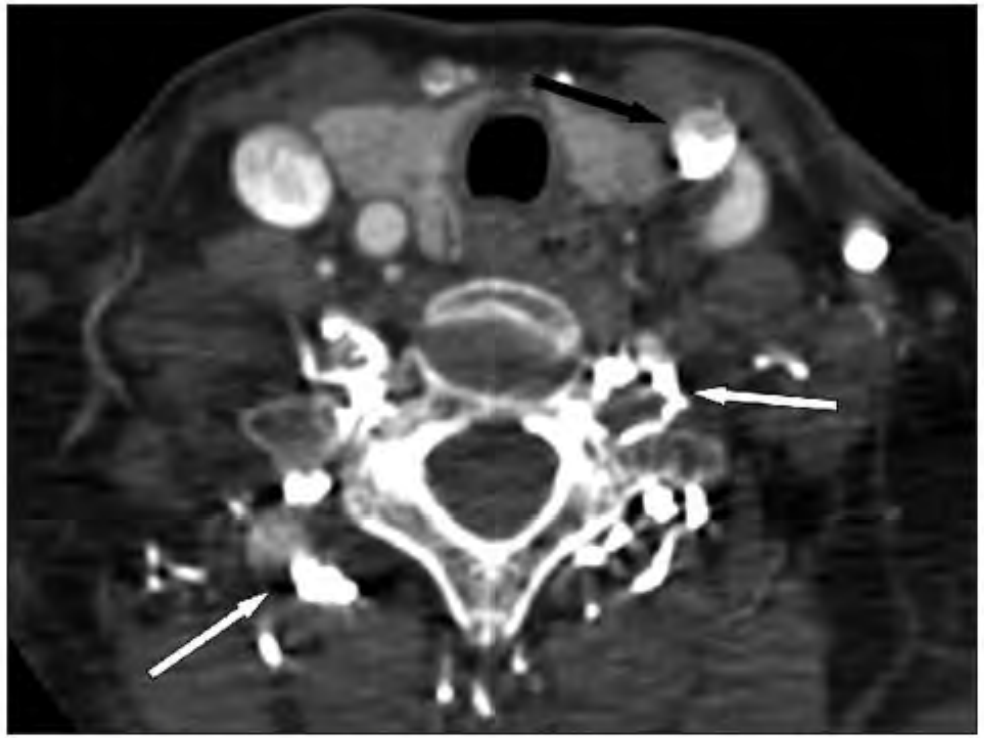

Figure 2. Reflux into the branching veins (paravertebral, external jugular veins) *(white arrows)* and the IJV *(black arrow)* are clearly shown on an axial source image.

SAFETY CONCERNS WITH CTA

- CACO=5.4 mSV (1.6 if only COW)
  - Chest CT =7-11 mSV)
- Total can be up to 16mSV if also obtain a Plain head CT=2.7mSV and a CTP=3.3-6.7mSV
- This is 5-6x annual average exposure of general population in US (3mSV).
- 100mSV exposure has lifetime attributable risk of cancer =16.5 per 1,000 for 20 yo and 2.1 per 1,000 for 80yo
- Contrast nephropathy risk is minimal

THANK YOU!

- *We need your help to help more patients!*